

Epithelium

Epithelial membrane

The principal functions of epithelium are :

1 -Production of under lining tissues from injury .

2 -Transcellular transport of molecules across epithelial layers.

3 - Secretion of mucous , hormones , enzymes .

4 - Absorption of materials from lumen (GIT) .

5 - Sensation ;taste pad.

6 - Contraction ;myoepithelial cell.

The epithelial tissue is present in two forms :

1 -Covering epithelium :as sheets of contiguous cells linked by junction complex and resting on specialized matrix (basement membrane) , that covered the body on its external surface and lined the body on its internal surface.

2 -Glandular epithelium which organized from invaginated epithelial cells to the adjacent tissues .

Basement membrane :

The basement membrane consist of two composition :

1 - Basal lamina : a cellular muco polysaccharids lamina produced by the epithelial cells to form supporting lamina to the epithelium .

2 - Reticular lamina : which formed from collagen and elastic fibers . Its produced by underlining connective tissue .

***Note** :The epithelia are a vascular and are supported and nourished by underlining connective tissue capillary bed .*

Classification of Epithelial membrane :

The epithelial membrane are classified according to the :

A –*Number of cell layers between basal lamina and free surface.*

1– Simple epithelium :it is formed from single layer of cells, and each cell contacts basement membrane and usually reach the free surface .

2 – Stratified epithelium :it is designed to withstands wear and tear , composed of more than one cell layers but only the basal layer resting on the basement membrane

B – According to morphology of the epithelial surface cells .

1 – Simple squamous epithelium:

Is composed of single layer of tightly packed ,flattened cells . When viewed from the surface, the nucleus is bulges to form look like fried egg in plate . Its lined the blood and lymphatic vessels ;therefore ,it called endothelium .but when lined the body cavities it called mesoththelium (peritoneum , pleura and pericardium),however this type of epithelium lined the alveoli .

2 –Simple cuboidal epithelium :

A single layer of polygonal- shaped cells . When viewed in a section cut the cells present a square with centrally rounded nucleus .This epithelium make up the duct of many gland , the covering of ovary and compose kidney tubules .

3 – simple columnar epithelium :

Consist of single continuous layer of tall hexagonal cells with a basal oval nucleus , this type of epithelium found in the lining much of the digestive tract , gall bladder .

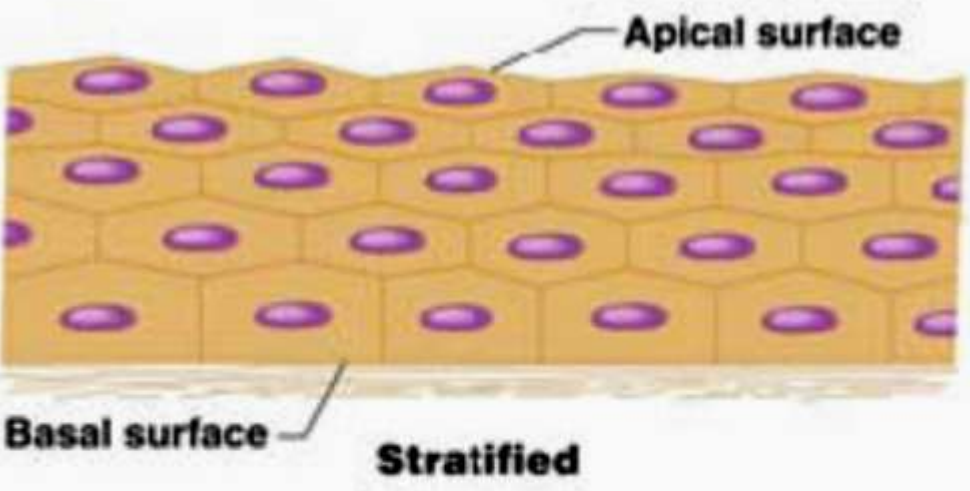
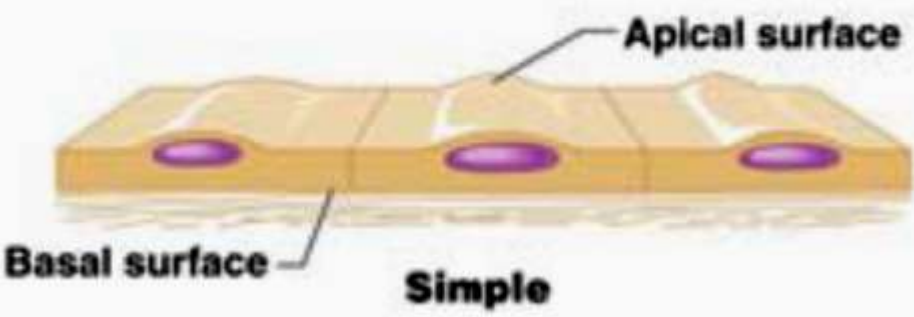
Simple columnar epithelium may be exhibit a striated border (micrvilli) : narrow finger like cytoplasmic processes projection from the apical surface of cell .

Goblet cell may be found with this type of epithelium .

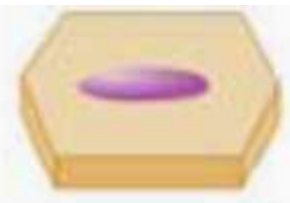
4 – Pseudo stratified columnar epithelium

Pseudo stratified columnar epithelium appears to consist of more than one layer of cells . All the cells are in contact with the basal membrane but not every cell reach's the luminal surface , the nuclei lie in different levels , causing the stratified appearance .

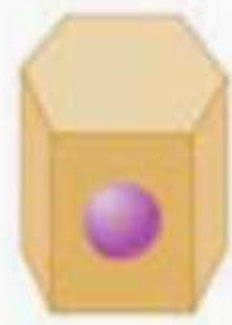The common form of this type of epithelium is ciliated :have cilia in the apical surface (with goblet cell) . Found lining trachea ,Epididymis , vas deference .




(a)



Squamous



Cuboidal



Columnar



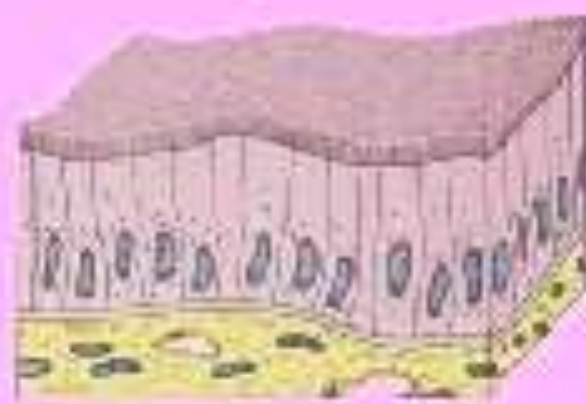
(b)



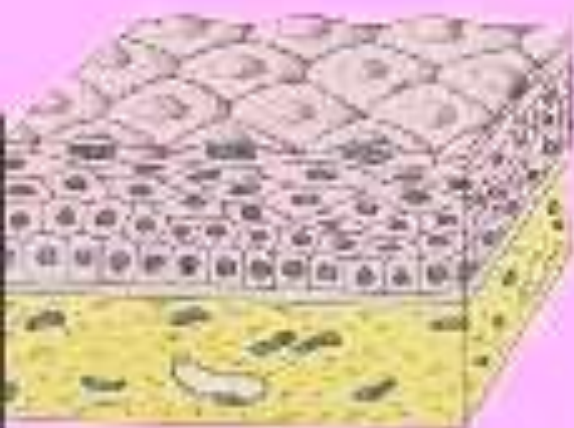
**simple
squamous**



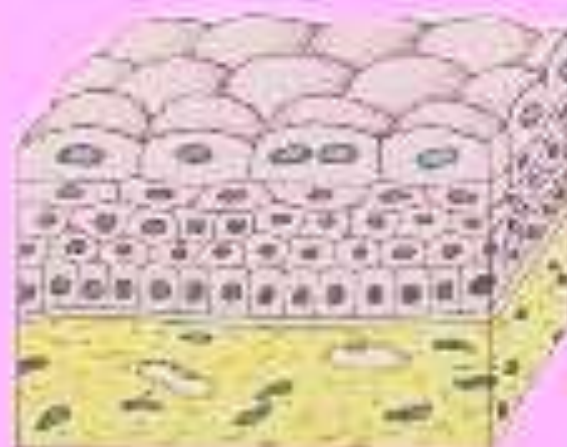
**simple
cuboidal**



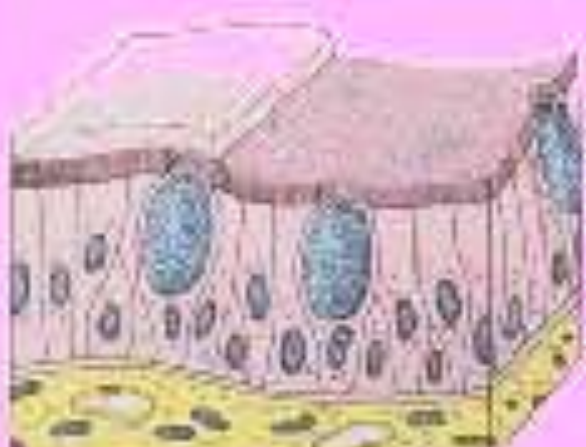**simple columnar
w/microvilli**



**stratified
squamous**



transitional



**pseudostratified columnar
w/cilia and microvilli**

Type of stratified Epithelium :

1 – Squamous

The stratified squamous epithelium may be keratinized or non keratinized . The non keratinized is composed of several layers of cells , only the deepest layer is in contact with the basement membrane and in the same time the cells of this layer are cuboidal in shape and the cells composing the surface of the epithelium are flattened . because of the surface cells are nucleated this epithelium is called non keratinized it is lining the mouth ,oral pharynx , Esophagus , Rumen and Vagina.

The keratinized type is similar to the stratified squamous non keratinized epithelium except that the superficial layers of epithelium are composed of dead cells whose nuclei and cytoplasm have been replaced with keratin m e.g. Epidermis skin

2 – Cuboidal :

Which contain only two layers of cuboidal cells, lines the ducts of sweat gland .

3 – columnar :

Is composed of several layer and the superficial layer is columnar cells . This epithelium is found only in few places in the body like , conjunctiva of the eye , some large excretory ducts ,regions of the male urethra .

4 – Transitional Epithelium :

That believed it is transitional between stratified columnar and stratified squamous . It is lining the urinary bladder , ureter , part of urethra . it is composed of many larger of cells those located basally are either low columnar or cuboidal cells while superficially there is several layer of pear cells or dome rounded cells where the bladder empty .the dome shaped cells become flattened and the epithelium become thinner when bladder is distended .

Junctional complexes (intercellular junction) :

Several membrane associated structures communicate between contiguous epithelial cells together .

1 – Zonula occludens :

Also known as a tight junctions ,located between plasma membrane and are most apically located junction between the cell of epithelia .

2 – Zonula adherence :

Are located just basal to the zonula occludentes and also encircle the cell .

3 – Desmosomes (Macula adherents)

It is spot weld like junctions also appear to be randomly distributed along the lateral cell membranes of simple and stratified epithelium especially in the epidermis